



## Tim's Surgical Column.

Just a reminder to get those lumps and bumps checked out before they create too much of a problem; in May we were presented with a great big problem which needed some major surgery to sort out!

This is a picture of Wally (name changed to protect his identity!) who came to us with a significant swelling around his back end, as you can see.

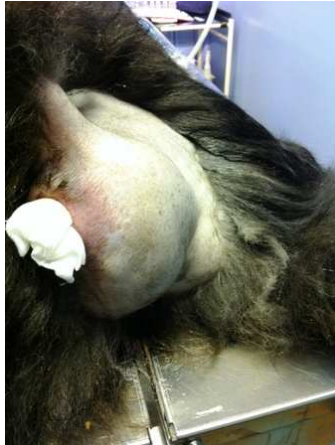

Figure 1: Perineal Hernia.

Suspicious of a condition called a Perineal Hernia, Wally was taken to theatre to reduce and repair the hernia. A hernia is a gap in the normal anatomy, ie a 'hole' in the muscle or the body wall through which fat and sometimes abdominal organs can prolapse. Perineal Hernia is usually seen in older male dogs which haven't been castrated - it is thought that an enlarged prostate gland can cause excessive straining which will cause the hernia.

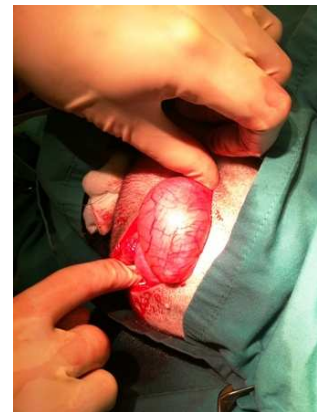

Figure 2: Retroflexed Bladder.

Wally's hernia was so large and severe that, amazingly, he had prolapsed his bladder and his prostate gland back out through the hernia. This would have made him very unwell very quickly - fortunately Wally was showing no other symptoms than a large, soft swelling around his backside.

Our surgical team were able to reduce the bladder and prostate back to their normal positions and to repair the hernia, so Wally can look forward to leading a normal life.

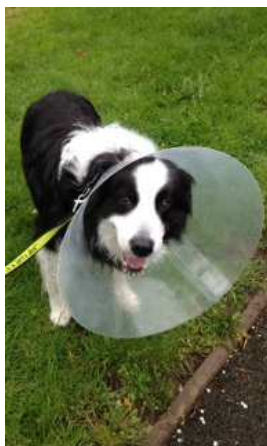

Figure 3: 'Wally' post-op.

This is a rather extreme example of one of the reasons we recommend castration of male dogs and cats and spaying (neutering) of females; there is a good chance that Wally wouldn't have had these problems if he had been castrated as a youngster!

So keep your eyes peeled on your pet and remember to get ANY suspicious lumps or bumps checked out; after all, it could be a prolapsed bladder in there!!




Figure 4: 'Wally' back to normal.